

FUNDUS PHOTOGRAPH READING CENTER

Non-study Specific

Standard 35mm Film Fluorescein Angiography (FA-F)

*(adapted from the Early Treatment Diabetic Retinopathy Study (ETDRS), Macular Photocoagulation Study (MPS) and the Age-Related Eye Disease Study (AREDS),
Manuals of Operations^{1, 2, 3})*

Effective Date: 13May2007, Supersede Date: New

Table of Contents

1.0	Overview	3
2.0	Photographer Certification	3
3.0	Uncertified Photographers (Follow-up Visits Only)	4
4.0	Fundus Cameras	4
5.0	Film and Processing.....	4
6.0	Standard Fields.....	4
7.0	Fluorescein Angiography	5
7.1	Fluorescein Injection	5
7.2	Timing.....	6
7.2.1	Early Phase	6
7.2.2	Mid-Phase	6
7.2.3	Late-Phase.....	6
8.0	Mounting and Labeling of 35mmFluorescein Angiogram Images	6
9.0	Retakes.....	7
10.0	Evaluation of Image Quality.....	8
11.0	Pointers on Imaging Technique	8
11.1	General	8
11.2	Patient Cooperation.....	8
11.3	Focus/Clarity	8
11.4	Stereoscopic Effect	9
12.0	References.....	9

1.0 Overview

The following is the University of Wisconsin-Fundus Photograph Reading Center's (UW-FPRC's) Standard 35mm Film Fluorescein Angiography procedure (FA-F). Please refer the documents specific to a study to determine if additional UW-FPRC procedures apply to a given trial.

Only UW-FPRC certified photographers are allowed to take Qualifying Visit (baseline) images unless an exception to this rule is granted (on a case-by-case basis) by the study sponsor. The sponsor may suspend patient enrollment if a site does not have a certified photographer available to take the qualifying images. Only under extraordinary circumstances may follow-up visit images be taken by an uncertified photographer (see section 3.0 below).

Clinical sites are strongly encouraged to have a minimum of two, but no more than three, certified photographers. Photographers are encouraged to contact the UW-FPRC's imaging consultants, Dennis Thayer thayer@rc.ophth.wisc.edu, Pamela Vargo vargo@rc.ophth.wisc.edu or Hugh Wabers wabers@rc.ophth.wisc.edu (608-263-9858) with any photography related questions. Pointers on photographic technique may be found in Section 11.0.

2.0 Photographer Certification

Photographers taking photographs (or images: the terms will be used interchangeably in this procedure) for studies evaluated by the UW-FPRC must be certified for the relevant procedure(s), *before submitting actual patient images.*

Photographer certification is specific for each study and each photographer requesting certification must submit a signed "UW-FPRC Photographer Certification Request Form" for each study. This form can be found in the *UW-FPRC Forms, Labeling, Study Conventions Information* section of the study specific documents. A copy of the form may also be available on the UW-FPRC website: <http://eyephoto.ophth.wisc.edu>, which may require a username and password. One form will be used for all imaging procedures associated with a given study.

Certification consists of (1) review of study synopsis/protocol and imaging procedures and (2) demonstrating the ability to perform the imaging procedure(s) by submission of images of acceptable quality. The second requirement may be waived if the photographer has prior certification at the UW-FPRC using **an identical procedure**, and has been active taking images, judged to be of good quality by the UW-FPRC, during the past 12 months. Photographers who are certified for **a similar procedure** may also be asked to submit sample photographs to become certified.

Photographers who are not eligible for certification on the basis of previous UW-FPRC certification should submit 2 fluorescein angiograms taken using this procedure. *The angiograms may be taken of patients with any retinal or choroidal disorder in whom angiography is being carried out for clinical purposes* Photographers previously certified for this procedure digitally (FA-D) electing to perform this procedure using 35mm film (FA-F) must submit one fluorescein angiogram. This allows us to check image quality (stereo effect, exposure, film quality, film processing and correct labeling/mounting of the film strips).

Photographers are encouraged to send complete submissions for each procedure that they are requesting certification (i.e. if 2 FA-Fs are required for certification please send both in one submission).

Photographers who meet certification criteria will receive confirmation of certification. Those who do not meet these criteria will receive feedback from the UW-FPRC imaging consultants, and may be required to submit additional sets of images. A plan for improving image quality may be necessary after three complete unsuccessful certification submissions.

Once a photographer is certified for a specific study they are certified for the duration of that specific study, even if they are inactive for more than one year.

3.0 Uncertified Photographers (Follow-up Visits Only)

On rare occasions during **follow-up** visits, when a certified photographer is not available, an uncertified photographer familiar with the procedure(s) may take the images. The uncertified photographer should review the imaging procedure(s) before performing photography to be certain they understand and follow the procedure(s). The name of the uncertified photographer should be entered on the film strip plastic sheet page label, as well as any other study documentation requiring photographer name. A brief description should be entered on the transmittal log explaining the reason an uncertified photographer took the images.

4.0 Fundus Cameras

The Zeiss FF4 (or similar models), Zeiss FF450-plus, Topcon TRC-50 series (50VT, 50X, 50EX, 50IA, 50IX and 50DX) and the Kowa and Nikon camera models used at the 30° or 35° settings are suitable cameras. Additionally, Canon cameras (UVi or similar models) used at the 40° setting are also suitable.

Cameras other than these may be substituted upon approval of the UW-FPRC. Approval may be obtained by submitting sample photographic sets, taken according to this procedure, to the Fundus Photograph Reading Center, Attention: Imaging Services, 406 Science Dr., Suite 400, Madison, WI 53711-1068.

5.0 Film and Processing

Kodak T-Max or Ilford 400 speed black and white films are recommended for angiography. The film may be processed by the clinic staff or at a local processing laboratory. The use of Kodak D-19, HC-110, or similar developer, is recommended. Development times will vary with developer concentration, temperature and camera flash setting. Any processing procedure that yields good quality negatives may be used. Proper care should be taken to adequately fix the film to insure archival image stability.

6.0 Standard Fields

The following descriptions of the standard fields assume that there are two cross hairs in the camera ocular, one vertical and the other horizontal intersecting in the center of the ocular.

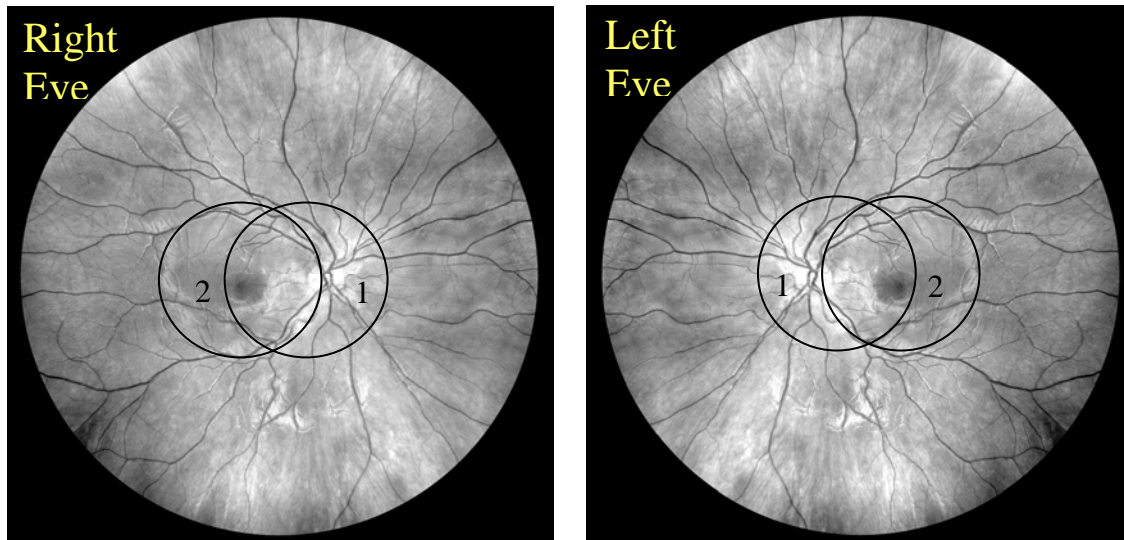


Figure 1

Field 1M - Disc: Center the temporal edge of the optic disc in the center of the cross hairs in the ocular.

Field 2 - Macula: Center the macula near the intersection of the cross hairs in the ocular. To keep the central gray artifact created by some cameras from obscuring the center of the macula, the intersection of the cross hairs should be placed about 1/8 – 1/4 DD above the center of the macula.

7.0 Fluorescein Angiography

The fluorescein angiogram contains stereoscopic views of 2 fields at specified times after injection. These fields include the macula (Field 2) of both eyes and the disc field (Field 1M) of the study eye. For Field 2, the camera should be centered near the center of the macula but not exactly on it, so that the artifact that is present in some fundus photographs will not obscure the center. If necessary, in trials investigating choroidal new vessels (CNV) Field 2 can be shifted by 1 disc diameter to include as much of the lesion as possible.

Stereo pairs should be taken shooting the right member of the pair first, followed by the left member of the pair. This sequence should be followed throughout the angiogram

Stereoscopic red-free photographs are taken of Field 2 in each eye prior to the injection of the fluorescein dye.

7.1 Fluorescein Injection

After the red-free images of both eyes have been taken, the camera is positioned for Field 2 of the study eye. Fluorescein is injected rapidly (less than 5 seconds if possible) into the antecubital or other convenient vein according to usual clinic procedures.

7.2 Timing

7.2.1 Early Phase

The first image of the early phase is taken at time "0"; that is, at the moment injection of the fluorescein dye begins. The second photograph is taken at the moment the injection is complete. These photographs are referred to as the "control" photographs. They serve to document the integrity of the interference filters. The time shown on the second frame documents the rate of injection.

Ideally, the control photographs are followed by a series of 10 to 16 exposures taken at 1 to 2 second intervals, beginning about 15 seconds after the start of fluorescein injection (sooner if fluorescein appears before 15 seconds or delaying the series if a slow circulation time is expected or the dye doesn't appear). The usual result is 5 to 8 stereo pairs following the control pair, typically culminating about 40-45 seconds after the start of injection.

7.2.2 Mid-Phase

After the early-phase photographs are completed the photographer takes stereo pairs of Field 2 and then of Field 1M of the study eye at approximately 60 to 90 seconds. Next, a stereo pair of Field 2 is taken of the fellow eye at approximately 2 minutes. Then, the camera is positioned back to the study eye and a stereo pair of Field 2 is taken between 2 and 3 minutes.

7.2.3 Late-Phase

A stereo pair of Field 2 in the study eye is taken at 5 minutes. Two final stereo pairs are taken of Field 2 in both eyes at 10 minutes.

8.0 Mounting and Labeling of 35mmFluorescein Angiogram Images

The original negatives are cut into strips of six images per strip, and are placed in a 10½ x 9-inch transparent plastic sheet containing six pockets per sheet.[†] A page identification label (Figure 2) is attached to each page of negatives. **When cutting the film into strips, the photographer should take care not to separate the members of a stereo pair (i.e., not to leave one member of the pair at the end of one strip and the second member of the pair at the beginning of the next strip).** It is recommended that the clinical centers retain a copy of the angiogram.

[†] The UW-FPRC recommends Print File Archival Preservers Style #35-6HB, available from Print File, PO Box 607638, Orlando, FL 32860-7638, phone 407-886-0008, website www.printfile.com.

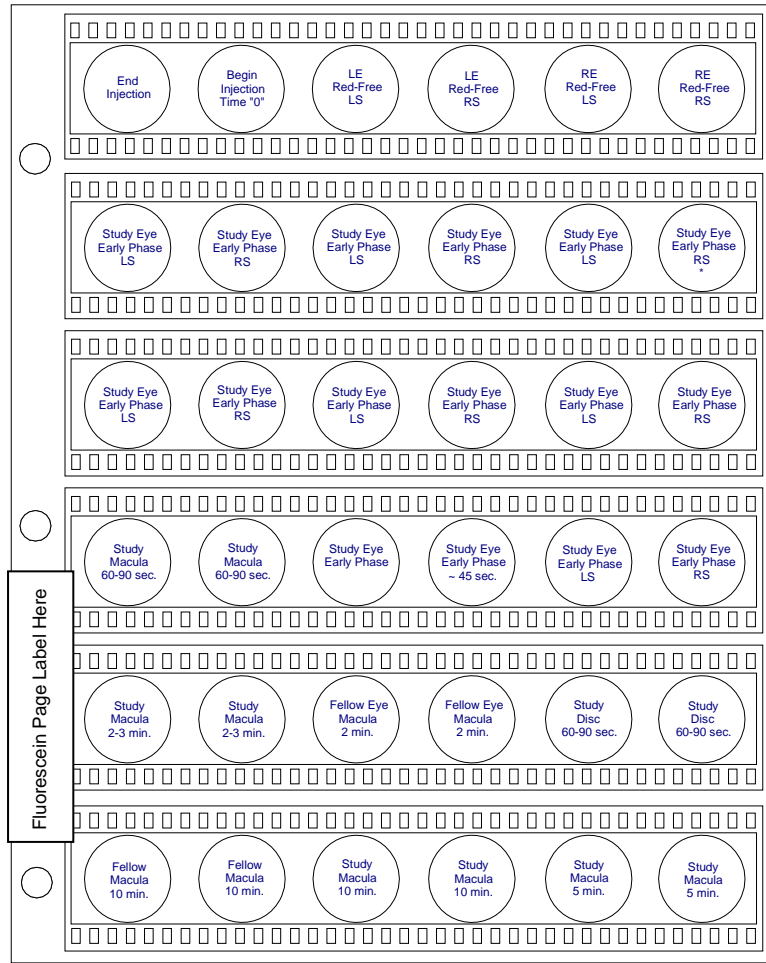


Figure 2

*5-8 stereo pairs taken beginning about 15 seconds after the start of fluorescein injection (or at first appearance of fluorescein, if sooner than 15 seconds or if a delay due to slow circulation time is expected).

For *certification images* if pre-printed page labels are not available please hand-label using a permanent felt-tip marker. The page label should indicate a patient identifier, photographer's name, date of photography and that the images are certification sets. Certification images will be returned upon clinic's request; otherwise they will be disposed of by the UW-FPRC.

For labeling of *study participant submissions* please refer to the information outlined in the *UW-FPRC Forms, Labeling, Study Conventions Information* section of this document.

9.0 Retakes

The fluorescein images should be evaluated for quality by the *principal investigator and/or photographer* (unless prohibited by Study Protocol) before submission to the UW-FPRC. If quality is not adequate for assessment of key features of the study eye, such as extent of macular edema, and if no irremediable cause of inadequate quality is present (such as lens

opacities or a pupil that will not dilate adequately), the images should be retaken before submission to the UW-FPRC. When images are considered ungradable because of poor quality, the UW-FPRC may issue a retake request.

10.0 Evaluation of Image Quality

Fluorescein angiogram images are reviewed and assigned a grade for overall quality. Grades of excellent, good and fair indicate that a set can be evaluated with no problem. Grades of borderline-explained and borderline-unexplained signifying that a set can be assessed, although the quality compromises the grading somewhat. Grades of inadequate-explained and inadequate-unexplained indicate that a set cannot be completely evaluated. The "explained" variant of borderline or ungradable is selected if the UW-FPRC grader sees media opacities in the fundus reflex (anterior segment) image explaining the reduced quality, or if the photographer records that the patient had difficulty cooperating.

Feedback will be provided to the photographers as needed to help with resolution of any problems. Special attention will be given to photographers having difficulty meeting study photo quality standards. If a certified photographer consistently fails to meet study standards, certification may be suspended.

11.0 Pointers on Imaging Technique

11.1 General

A 4X or 5X magnification stereoscopic viewer for examining fluorescein angiogram images is required, so that the photographer can critically examine his/her work and make appropriate corrections in technique, as well as correctly cut film strips to not separate stereo pairs.

11.2 Patient Cooperation

Photography of the photophobic subject can be very challenging for the photographer and uncomfortable for the subject. Minimizing the number of flashes and the length of time the eye is exposed to a bright viewing lamp are two things that can help make the photography procedure more comfortable. Additionally, keeping the view lamp as low as possible (maybe even dimming the room lights) can help make the photography procedure more tolerable. Patients should be asked to blink to help keep the cornea clear.

If the subject has great difficulty tolerating the screening visit photography procedure and the photographer thinks this will lead to a problem at follow-up visits, the situation should be discussed with the principle investigator and/or coordinator and consideration should be given to not enrolling the subject in the study.

11.3 Focus/Clarity

Remember that the best image quality can be acquired if corneas are not disturbed by prior examination with a diagnostic contact lens.

Constant attention must be paid to keeping the cross hairs in the camera ocular in focus; otherwise the images will be out of focus. Proper camera-to-eye distance should be maintained to avoid haziness and artifacts.

If it is not possible to get the entire photographic field in crisp focus, the photographer should concentrate on getting the center of the field in focus, sacrificing a bit on the periphery if necessary.

When the photographer moves between fields, **he/she should refocus on retinal vessels near the center of the field.** *Failure to do so results in images that show the foveal area to be slightly out of focus while the periphery is in focus.*

A common problem is focusing below the surface of the retina. Images which include the disc (Fields 1M and often Field 2) sometimes show clear focus on the bottom of the cup, while the retina is slightly out of focus. Some photographers use the lamina cribrosa (at the bottom of the cup), the disc margin, or the granular pattern of the pigment epithelium for focusing. Instead, it is preferable to focus on fine retinal vessels. Since the depth of focus is greater posterior to the plane of absolute focus than anterior to it, it makes sense to err on the side of focusing slightly above the retina rather than too deep. This should keep both the anterior surface of the retina and the pigment epithelial background in focus. Such a strategy is of special importance when macular edema is present.

11.4 Stereoscopic Effect

Dilation of the pupil to at least 6mm is important to permit good quality stereo photography. *If the pupils cannot be dilated to at least 4mm for the screening visit, the subject should not be entered into the study.*

The technique described by Allen⁴ is used for taking non-simultaneous stereo fundus images. The camera **should not be rotated or pivoted for stereo images**; instead, it should be moved laterally from right to left with the joystick (or by sliding the camera base on its table, if preferred). About 2mm is the minimum separation between members of the stereo pair to be aimed for when moving the joystick or sliding the camera.

Stereo pairs should be taken shooting the right member of the pair first, followed by the left member of the pair. When obtaining stereo pairs, care should be taken that at least one member of the pair is of good technical quality with crisp focus. In many cases, it will be possible to obtain good quality in both members of the pair, but if this is not the case, *the aim should be to obtain good quality in one member and **some** stereo separation between the members, accepting **somewhat** poorer quality in the second member of the pair, if necessary.*

12.0 References

1. Early Treatment Diabetic Retinopathy Study Research Group, Manual of Operations. Chapter 13. Baltimore: ETDRS Coordinating Center, University of

Maryland. Available from: National Technical Information Service, 52285 Port Royal Road, Springfield, VA 22161; Accession No. PB85 223006/AS Chapter 13.

2. Macular Photocoagulation Study Group, Macular Photocoagulation Study: Manual of Procedures. MPS Coordinating Center, Baltimore, MD. Available from National Technical Information Service, 5285 Port Royal Road, Springfield, VA 22161; Accession No. PB90-207903.
3. Age Related Eye Diseases Research Group, Manual of Operations. Chapter 8. Potomac, MD: AREDS Coordinating Center, EMMES Corporation, 11325 Seven Locks Road, Suite 214, Potomac, MD 20854.
4. Allen L. Ocular fundus photography. *Am J Ophthalmol* 1964;57:13-28.

Informational Only